EVALUATION OF A HIGH-POWER BLUE DIODE LASER (MILESMAN BLAUMAN®) FOR DERMAESTHETICS TREATMENTS.

HISTOLOGICAL AND CLINICAL VERIFICATIONS.

Mario A. Trelles M.D., Ph.D.
Vilafortuny Dental & Medic-Surgical and Instructional Centre. Plastic Surgery Section.
Al Wasl Rd – Jumeirah, Dubai (UAE)

Milesman Blauman® is a high power diode laser, programmable for different fluences and pulse frequency, emitting a wavelength of 450nm (blue spectrum), and initially designed for the treatment of acne. In 2022 we presented the results of a pilot trial to evaluate the efficacy and safety of the equipment for this indication, with very satisfactory results. However, early verifications also indicated other possibilities for this laser, due to its potential vaporization, coagulation and cutting capabilities. These features would make it possible to treat many other types of skin lesions. At present, lasers with similar characteristics are being incorporated with great success for dental and oral cavity treatments, but there is little information on their possible applications in skin.

Here we analyze the theoretical groundwork of Milesman Blauman® interaction with biological tissues, based on the literature, and provide a series of histological and clinical verifications, carried out at our center, which demonstrate the possible uses of this laser for various dermaesthetic treatments in patients.

• **Keywords.** diode laser, 450 nm laser, blue laser, vaporization, coagulation, cut, acne vulgaris, dilated pores, vascular lesions, pigmented lesions, skin rejuvenation.

EFFECTS OF THE 450nm BLUE DIODE LASER ON BIOLOGICAL TISSUES

High-power diode (semiconductor) lasers emitting at 450nm are a recent addition to the market and at present, published research studies in the dermaesthetics field are few and far between and of little relevance. According to the information in the Medline database all the studies published with these lasers (blue, 450nm) come from the field of dentistry and oral cavity surgery, with advantageous results for multiple interventions with respect to other lasers available commercially (1-6). Thus, Milesman Blauman® emerges as the first laser with these characteristics designed for direct application to the skin, and represents an important new research tool in dermaesthetics. If we take into account the parallels between the tissues of the oral cavity and the skin, in terms of the mechanisms of action on biological tissues, it is to be expected that the actions and advantages observed in the dental field could occur in the dermatological field (1-6).

In 2016, Reichelt et al. investigate a new diode laser (450nm) to verify the effects on soft tissue microsurgery at the cellular level (1). They compare the results obtained with another diode laser (970nm) of conventional use, in terms of damage caused. On the basis that the absorption spectrum of hemoglobin and melanin is increased between 400-450nm, the new laser should have an excellent coagulation capacity, limiting deep penetration during incisions in monolayer cell cultures.

The results were better with the 450nm laser, because hemoglobin and melanin absorb blue light very well (1).

In 2017, Braun et al, based on research by Reichelt and other authors, test the cutting capability using a 450nm diode laser with similar characteristics to the previous one but made by a different manufacturer. They postulate that high precision surgical cuts can be achieved given the blue light absorption properties of soft tissues. Experiments on porcine oral mucosa demonstrated that precise cuts could be made deeper than those obtained with the 970nm diode laser. Comparing 450nm and 970nm lasers, with different modalities (contact/non-contact), and different dosimetry, they observed that the deepest cuts were only achieved with the 450nm laser in contact mode. A higher energy density per unit area is reached due to the targeting that can be achieved due to the spacer, with an optimal focal point of a smaller diameter. In this way, depths between 0.5-1mm were reached. The most important aspect of the study is that the 450nm laser not only made deeper cuts, but did not cause unnecessary damage to the surrounding tissue. Even in non-contact mode the 450nm laser successfully cut with little denaturation of the adjacent tissue (2).

Other recent studies confirm and build upon these results. Palaia et al. ascertain ex vivo, in great detail, the thermal effects of the 450nm diode laser on pig carcass tongues. They evaluate five dosimetric modalities irradiating in continuous emission and pulsed emission. The thermal damage observed was less than 1 mm, with no significant damage to the surrounding tissue. The injury to the epithelium was minimal, but greater damage to connective tissue was observed, especially when using medium potencies in continuous mode. In sum, the expected result is obtained, given the greater vascularization of the connective tissue and the high affinity that blue has for the hemoglobin chromophore; therefore, it is to be expected that the dermis will be more affected or damaged than the epidermis. Better results were obtained in pulse mode than in continuous mode, due to limiting the time of action of the energy during laser emission, or, similarly, by respecting the TRT (Thermal Relaxation Time), which allows a better recovery of the treated tissue by carefully focusing the heat on the target to avoid unnecessary damage (4).

As with other laser treatments, the risk of infection of the treated areas is lower than with conventional alternatives. In the case of the 450nm blue laser, significant bactericidal activity has been observed in controlled trials. One of the most demonstrative studies is that of Wenzler et al. in randomized groups of patients undergoing endodontics. They quantify the percentage of bacteria removal after chemo-mechanical treatment of the dental radicular canal. The 450nm blue laser alone, applied at a power of 0.59W in continuous mode, achieved a reduction of bacteria close to 60%, quantified by bacterial colony forming units (CFU/ML). In the group in which only sodium hypochlorite was used, the reduction in bacterial load was approximately 80%. In the group treated simultaneously with hypochlorite and laser, the bactericidal effect exceeded 90% (6).

These and other studies confirm, in practice, that the theoretical capabilities of the 450nm blue laser (coagulation, vaporization, cut and disinfection) are successfully used in dentistry and oral cavity surgery (1-6). There is no information on the possible uses in dermaesthetics, and the first skin verifications carried out in this area are those reported in this study.

The application of Milesman Blauman® on test models (tomato, avocado shell and eggshell), porcine and human skin, and especially on different types of skin lesions in outpatients, verifies that this laser equipment allows effective coagulation, vaporization and cutting actions, by the thermal effect of laser pulses, properly programmed, with minimal residual thermal damage and with good and fast clinical recovery.

• **Figure 1.** Removal of skin lesions by thermal vaporization with Milesman Blauman®.

Figure 1 outlines the basic mechanism of action for the removal of skin lesions, based on the tests carried out with this equipment.

It is ascertained that marking the target with a black ink marker, which intensely absorbs blue light, can increase clinical efficacy in certain interventions. Essentially, the ink acts as an exogenous artificial chromophore that strongly and preferentially absorbs the 450nm emission promoting the vaporization of the lesion while avoiding thermal propagation, with significant improvement in the obtained results. As developed in the discussion section, the creation of an optical barrier with this laser offers significant advantages.

In contrast to CO_2 lasers, blue light is hardly absorbed by water, so the vaporization and cutting capacity is lower, and often not very noticeable if the optical barrier mentioned above is not established. For this reason, the working mode and the dosimetries used (especially power, pulse length and pause between pulses) are crucial to obtain the best possible results. The discussion section will elaborate on the need for future clinical trials to establish a protocol of procedures and dosimetries for this equipment.

Figure 2 illustrates the three thermal effects, which are achieved by defocusing the beam as the handpiece is moved away, or by focusing to the maximum, where the spacer defines the maximum focus (0.5mm diameter spot).

If the emission power is maintained, but the beam impact diameter (or the spot of the beam impact) is increased, the energy decreases. If we would like to maintain the irradiance (i.e., the same energy in the spot area) we must increase the irradiation time. The emission for a long time cancels the selectivity of action and acts as a "plate" system with a non-specific thermal effect, where the energy will be absorbed



• **Figure 2.** The main thermal effects according to the degree of focalization with Milesman Blauman®

preferentially by the target chromophores, but not selectively. On the contrary, if the chromophore is present on the target, according to the laser emission band, it is possible to achieve selective and very precise cutting, vaporization or coagulation.

The general principles of laser-tissue interaction are confirmed, with the advantage of the high absorption of blue light by the chromophores hemoglobin, oxyhemoglobin and melanin, necessary to obtain the thermal effect based on the Grotthus-Drapper law and the theory of Selective Photothermolysis. It is thus observed that the thermal effect is directly proportional to the irradiation time, and that the depth of the incision depends on the applied energy concentrated per irradiation area. When the power is maintained and the beam is defocused, the energy density decreases per area, achieving the effect of coagulation or vaporization depending on the time of action of the energy on the target.

MILESMAN BLAUMAN®: TECHNOLOGY AND CHARACTERISTICS

Milesman Blauman® (Milesman, Gijón, Spain) is a high-power laser programmable for different fluences and pulse frequency, which emits a blue beam, in pulsed mode, with a wavelength of 450nm. Its main effect is thermal and its main mechanism of action is based on the principle of selective photothermolysis, similar to the lasers used to treat tissues in dentistry and the oral cavity, as indicated in the aforementioned publications.

The application of innovative technology has created a simple, technologically advanced, compact and ergonomic structure, consisting of a central unit, a pedal and a handpiece connected with a cable, which makes this equipment easy to use and transport. All of the laser functions can be controlled on the touch screen on the central unit. The spacer that is incorporated into the handpiece indicates the maximum focusing of the beam to obtain the desired effect on the target and means that the handpiece can be placed on the skin.

Milesman Blauman® 450nm Diode Laser Console and Handpiece

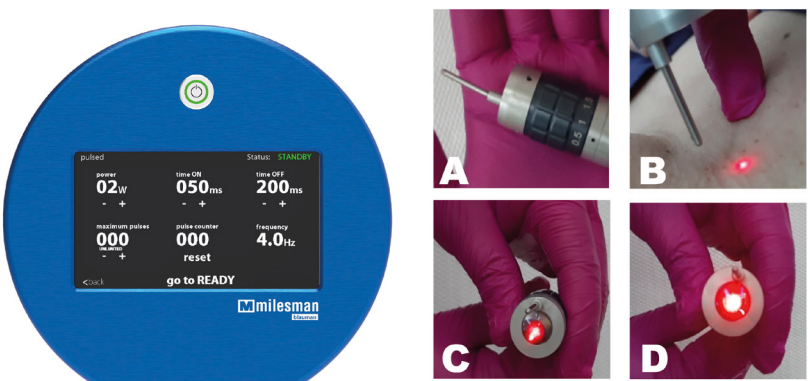

HANDPIECE IN DIFFERENT FOCUSINGS

Powerful portable laser emitting in the blue band at 450nm, offering multiple forms of pulse modulation and beam focusing / defocusing, registered for the treatment of inflammatory acne

• **Figure 3.** Milesman Blauman® console in the version used for this study. Small system including software and connection for footswitch and fiber for laser energy transmission. The display shows the programmable parameters and includes the safety and shutdown mechanisms required for Class 4 lasers. It shows the handpiece used specifically for our tests. At its distal end it has a 2.5cm long spacer which, once resting on the skin, defines the targeting diameter (0.5mm), and when it is moved away, the beam is defocused in order to achieve the vaporization and coagulation effects.

The laser can reach up to 10 W power and pulse lengths from 1 to 300 ms. These characteristics place it within Class 4 of the safety regulations: UNE EN 60825-1/Al 1: 1997, with the addition UNE EN 60825-1/A2: 2002, currently in force. Its clinical use must be carried out under the protection measures for Class 4 lasers (7).

The maximum focus (0.5 mm spot diameter) is used, for example, in the case of acne, to vaporize the most apical part of the lesion. When the laser is operated, it seeks precise absorption of the energy while avoiding the risk of thermal runaway. To this end, the apex of the papule or pustule is painted with a black marker pen to form an optical barrier that absorbs the energy of the 450nm beam intensely, vaporizing the most superficial layer

of keratin and breaking up the acne lesion. By using the same number of pulses in a defocused manner, moving the spacer away, the lower energy per area and longer total irradiation time, allows superficial disinfection of the lesion and promotes trophism of the treated area more widely (8).

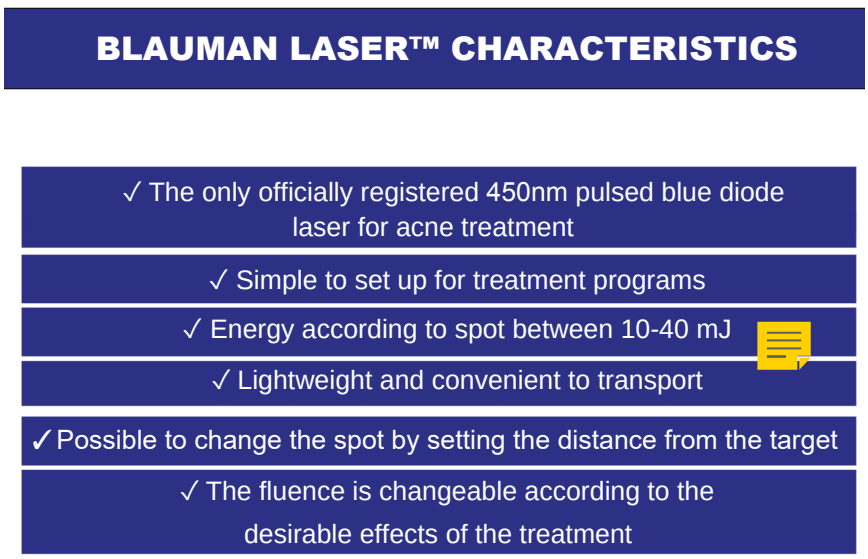

• **Figure 4.** Main features of Milesman Blauman®.

APPLICATIONS OF MILESMAN BLAUMAN® IN DERMAESTHETICS

The preliminary tests indicate that Milesman Blauman® can treat acne papules and pustules, and enlarged pores, but also many other lesions due to its vaporizing, coagulating and cutting effects. The vaporization effect helps to deal with different types of pigmentations (whose chromophore is melanin), such as cases of dermal nevus, solar lentigines and melanosis, and is also effective for facial rejuvenation. The coagulation effect makes it possible to treat vascular lesions, as we have seen in the case of facial telangiectasias. Finally, although it is not an ideal laser to be used as a scalpel, we demonstrate the cutting effect and coagulation performed with this equipment on skin and labial mucosa, respectively. Below are some of the results obtained for all these indications.

TREATMENT OF ACNE PAPULES AND PUSTULES

In 2022, we completed a pilot trial with masked outcome assessment to determine the efficacy, safety and practicability of Milesman Blauman® in the treatment of acne lesions considered targets (papules and pustules). Eleven biopsies of lesions on the back treated in a single session were analyzed to assess the cutaneous structural damage caused by the treatment, and how this damage is repaired (8). Ten patients were studied in which, during their single sessions, a total of 97 target lesions on the face were treated. Histological follow-ups of up to 6 weeks ascertained good repair of the treated lesions at both epidermal and dermal levels, with initial rupture of the dermo-epidermal barrier, rapid restitution, and progressive reduction of inflammatory infiltrates in the dermis, without formation of macroscopic scars. Three weeks after treatment, the number of target lesions on the face, as identified by a blinded evaluator, decreased by 64%, statistically significant ($p=0.0051$). The procedure was well tolerated by the patients, with excellent satisfaction with the results for both the therapist and the study participants. Despite these good results in the reduction of inflammatory acne lesions, it should be emphasized that in the case of acne treatment, laser should be used as an adjuvant or complementary treatment to conventional treatments and not as the only tool, except in those patients who refuse to receive topical or systemic treatments after having been genuinely advised by an expert physician.

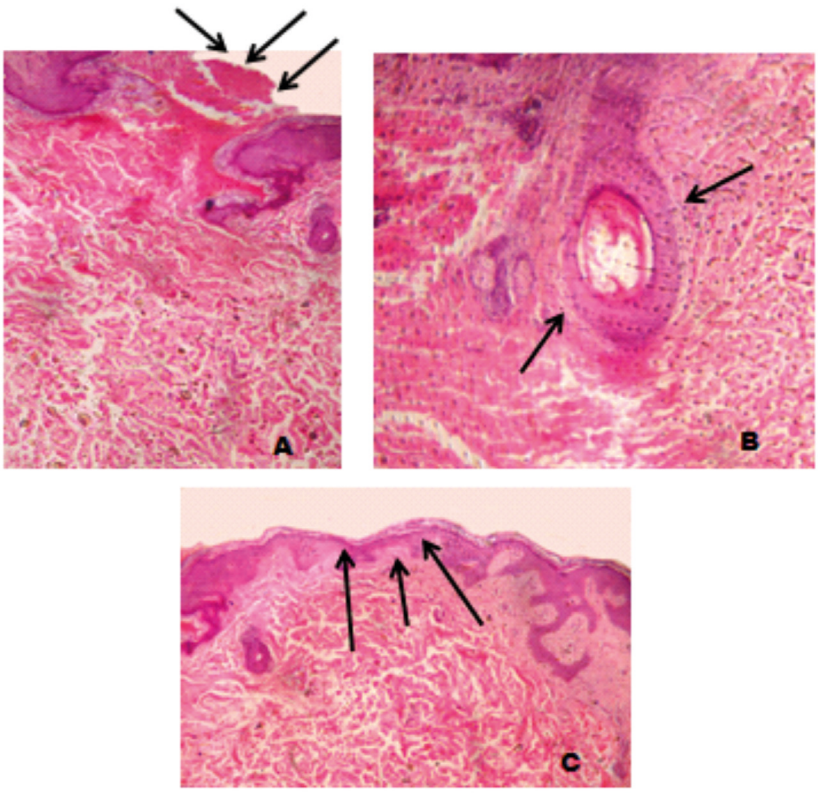

• **Figure 5.** Sequence of biopsies corresponding to acne pustules located on the back treated with Milesman Blauman® (8)

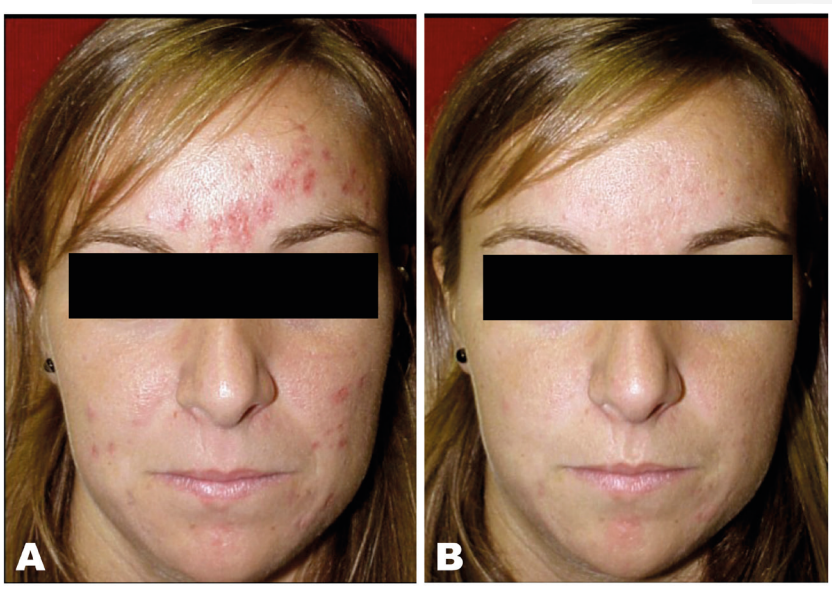

• **Figure 6.** Inflammatory acne treated with Milesman Blauman®. A: before treatment, B: after treatment.

Figure 5 shows histological images of pustules treated with Milesman Blauman®. Image A shows a pustule recently treated with the laser. It is observed that the contents have been evacuated, together with a residue of hematic secretion (arrows). The epidermis is clearly broken, while in the image B, corresponding to a similar untreated pustule, the hair follicle is observed with abundant lymphocytic infiltration mainly in the papilla and hair shaft (arrows). Image C corresponds to a pustule two weeks after treatment in active reparative phase. The epidermis is thin and with scarce keratin, indicating an early stage of epidermal restitution (arrows). In the dermis scarce and spaced fibers are seen, probably edematous residue, and some hair follicles surrounded by residual inflammatory infiltrate.

Figure 6 is representative of the good results obtained in the treatment of inflammatory acne. The patient is 27 years old, phototype II-III, with multiple acne lesions on the face and back, and especially on the forehead, temples and cheeks. No endocrinological or gynecological abnormalities were detected, with ovarian ultrasound without the presence of cysts. Previous topical treatments proved to be ineffective. The image shows the result three months after three treatment sessions, together with the topical application of retinoic acid 0.5%, every 24 hours. Treatment of dilated pores.

TREATMENT OF DILATED PORES

The pores of the skin are the orifices of the pilosebaceous follicles. When they are dilated (dilated or open pores), they are visible and constitute an aesthetic problem, especially in the nasal area, but they can appear in any area of the face. They are frequently associated with acne, although they may be due to many other causes such as genetic predisposition, hormonal changes or skin aging. Among the different options for closing dilated pores, laser treatments are the most effective. Many lasers have been used to reduce pore size, with good results, without a clear understanding of the mechanism of action. The most widespread hypothesis is that pore closure is the consequence of a photothermal effect on the dermis, causing a remodeling and restructuring of the dermal collagen, together with changes in the epidermis, leading to a reduction in pore diameter.

The special characteristics of the blue light offer good theoretical expectations for effective results in reducing pore size without occluding or destroying pores. It is important to preserve the function of the pores, as they play an important role in the secretion of sebaceous filament that when released to the outside of the skin improves the physiological lubrication of the epidermis.

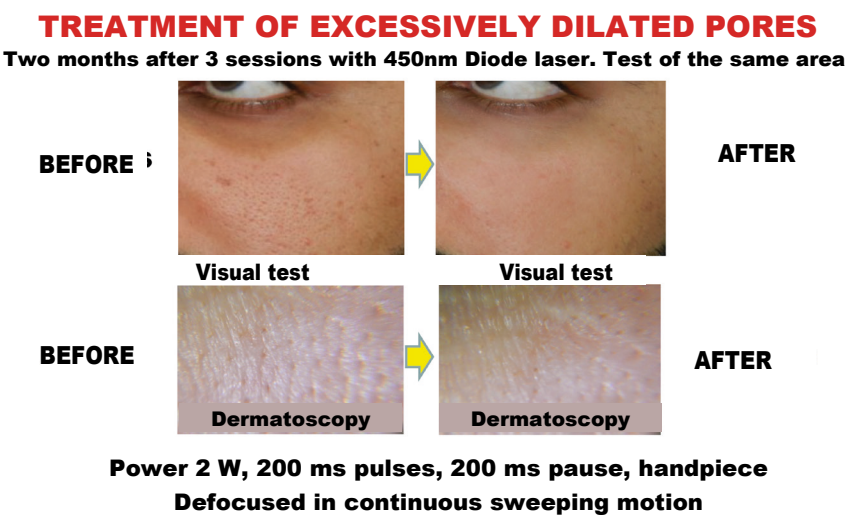

• **Figure 7.** Reduction of dilated pores using Milesman Blauman® observed by standardized clinical photography and dermoscopy.

A detailed analysis was made of five patients who underwent a monthly laser session for three months. The dosimetries used were: Power 2 W, pulse duration 200 ms, frequency 3.4 Hz, pause between 200ms pulses, in defocused mode with sweeping motion. Clear improvements were obtained, assessed by clinical and dermoscopic photography, consistent with good satisfaction of all the patients treated. Images of a representative case are shown (Figure 7), illustrating the significant reduction in the number of dilated pores found in the series before and after treatments ($p<0.05$). The statistical analysis considered the number of dilated pores in clinical photographs and computerized comparison of dermoscopic images.

Based on previous knowledge in the treatment of dilated pores with different lasers, we consider that the results obtained with Milesman Blauman® are effective and safe for pore diameter reduction. In the particular case of treatment of dilated pores, this equipment may be the first choice.

TREATMENT OF PIGMENTED LESIONS

The vaporization effect makes it possible to treat numerous lesions, such as rhinophyma, dermal nevi, keratoses, xanthelasmas, epidermal nevi, multiple plaque keratoses, and, especially, various pigmented lesions. Figures 8-10 show some clinical results obtained by vaporization with the Milesman Blauman® equipment.

We determined that it is possible to treat areas of melanosis by employing squid ink as an exogenous chromophore (Figure 10). Image A corresponds to the initial state before the two treatments. The equipment was programmed to emit a 3W

Diode laser treatment 450nm: VAPORIZATION EFFECT ON HIGH BENIGN SKIN LESIONS

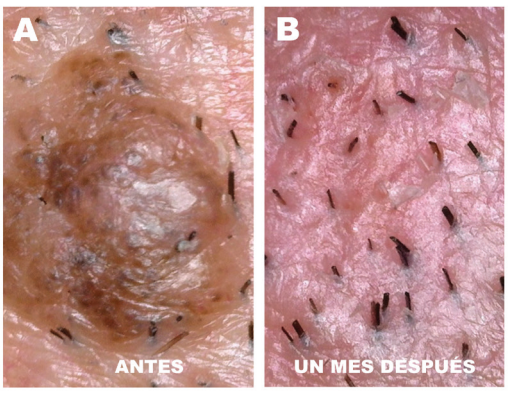

A) Dermal nevus with s e pigment and hair component, located in the beard area. Dermatoscopic examination with no signs of malignancy. B) Result one month after treatment by vaporization with Blauman® 545 nm Diode laser. The programming used was 5 W, pulse of 100 and pause of 100 ms, with a beam diameter of 2 mm.

• **Figure 8.** Dermal nerve treated with Milesman Blauman®.

with 10 ms pulses, 200 ms pause and approx. 3 mm beam diameter. A squid ink rich in melanin was used (Lab. Sesderma, Valencia), marketed as a dermocosmetic product to activate tanning. Such a product can also be used to provide melanin to white hair to achieve photoepilation (9,10). It was applied in two layers, with a brush, uniformly all over the face. One hour later, the face was washed with water and neutral soap and the area to be treated was irradiated by slowly moving the handpiece in a sweeping motion. At the end of the laser irradiation, Prednicarb ointment was applied followed by a repairing dermocosmetic (TT1 Cosmética Activa, Lab. Profarplan, Barcelona). This procedure was applied for 3 days and then only with repairing cream until the skin is exfoliated and dried, applying the dermocosmetic three times a day. Once the scabs have come off, it was recommended to avoid sun exposure and to use sunscreen 50 SPF three times a day. The treatment was repeated at six weeks with the same protocol, recommending the application of 0.25% Retinoic Acid daily at night followed by a moisturizer. Image B shows evident improvement. The melanin-rich squid ink applied on the skin acts as a barrier and its impregnation in the most superficial cells of the epidermis achieves the absorption of the 450nm band of the laser and protects from thermal spread and risk of burns. Facial rejuvenation

Diode laser treatment 450nm: VAPORIZATION EFFECT
Removal of solar lentigo with deep pigmentation

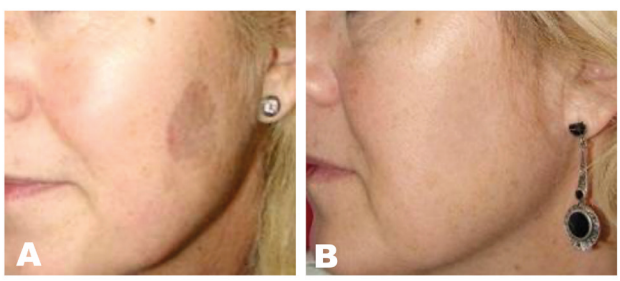

A) FORE. The lesion had received several unsuccessful treatments, and dermoscopic examination showed no signs of malignancy. B) It corresponds to three months after a single treatment with a 450nm Diode laser: 3 W, 10 ms pulses, 4 Hz frequency, 200 ms pause and 2 mm beam diameter. It was recommended to use Retinoic Acid 0.5, daily on the lesion once the scabs fell off, together with sunscreen 50 SPF daily and frequently.

• **Figure 9.** Solar lentigo treated with Milesman Blauman®.

Diode laser treatment 450nm: VAPORIZATION EFFECT
Removal of Mid & Deep Pigmented Melanosis

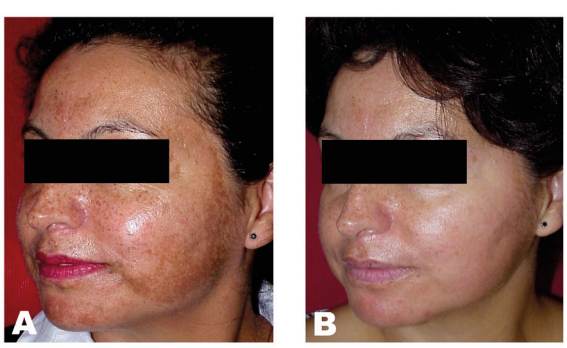

• **Figure 10.** Melanosis treated with Milesman Blauman®. Before (A) and after (B) two treatment sessions.

Milesman Blauman® can also be used for facial rejuvenation. Here we present a case of tissue vaporization achieved with the use of a squid ink optical barrier (Figure 11).

FACIAL REJUVENATION

Milesman Blauman® can also be used for facial rejuvenation. Here we present a case of tissue vaporization achieved with the use of a squid ink optical barrier (Figure 11).

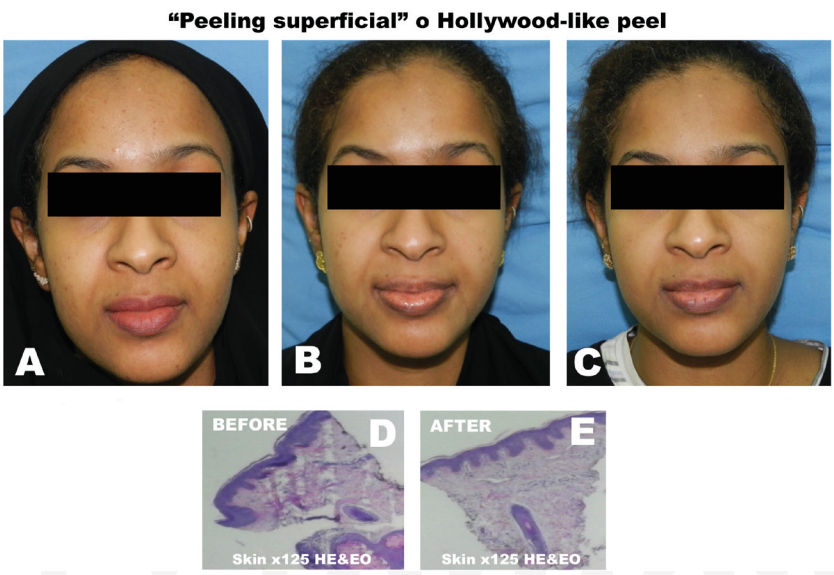

- **Figure 11.** Facial rejuvenation with Milesman Blauman®. Two treatments were carried out at two months intervals. A: before the two treatments. B: two months after the first treatment. C: two months after the second treatment. D: histologic sample before surgery. E: sample after the intervention.

The laser was programmed to emit at a power of 2 W, with pulses of 10 ms, 200 ms pause and approx. 3 mm of beam diameter. Two layers of melanin-rich squid ink were applied with a brush evenly over the entire face and especially on the lower third, where the patient noticed the most skin darkening. One hour after the application of the artificial pigment, it was washed with water and neutral soap and irradiated by moving the handpiece in a sweeping motion at a regular speed for 3 minutes. At the end of the laser irradiation, Prednicarbate ointment was applied followed by Dermocosmetic Repair (TT1 Active Cosmetics, Labs. Profarplan, Barcelona). This procedure was applied for 3 days and then only the repair cream was used until the thin layer of desiccated peeled off. It was then recommended to use sunscreen 50 SPF three times a day and avoid sun exposure. The treatment was repeated at six weeks with the same protocol, recommending the application of 0.25% Retinoic Acid daily at night followed by a moisturizer. After about 30 minutes the moisturizer was applied.

As seen in the case of melanosis, squid ink applied on the skin acts as a barrier. Its permeation in the most superficial cells of the epidermis allows absorption of the 450nm band of the laser and protects from thermal spread and reduces the risk of burning. Topical anesthesia is not recommended because pain is an indication of heat accumulation.

Image C, two months after the second treatment, appears to show improved skin texture and homogeneity, especially in the lower third, but the changes are insignificant. With only superficial exfoliation of the skin, the process reverts easily with no identifiable clinical outcomes. However, the patient reported better skin texture, tone, and color, and was very satisfied with the result.

To verify possible histological changes, the preauricular areas were treated in the same way as the rest of the face, and biopsies were taken with a 1 mm punch. Before treatment (D), signs associated with elastosis are observed, and a less undulating epidermis after treatment. Three months after the second treatment (E), the epidermis has an undulating appearance and a broad band of wellestablished collagen is observed. It should be noted that the skin appears without keratin, probably due to the use of retinoic acid as a maintenance treatment.

TELANGIECTASES IN THE NOSE

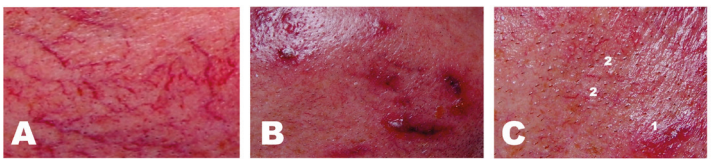

1 W, 0.5 mm beam diameter, 40 ms pulses, 100 ms pause.
2 sessions without anaesthesia

• **Figure 12.** Telangiectasias in nasal area treated with Milesman Blauman® A: Before, B: Immediately after, C: three weeks after (first treatment session)

Diode laser treatment 450nm:
COAGULATION EFFECT

1 W, 0.5 mm laser beam diameter, repeated 40 ms pulses throughout the capillary silhouette, with 100 ms pause between pulses. Three treatment sessions without anesthesia

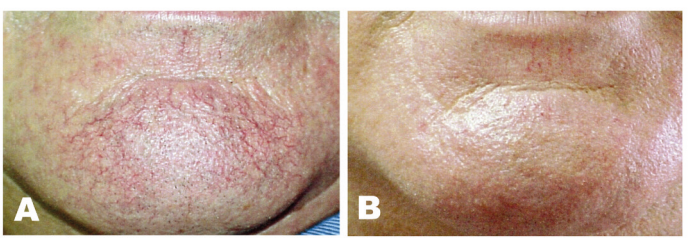

Small capillaries of reduced diameter

Two months after the third treatment, which were carried out one month apart

Note. In fine facial telangiectases, a greater number of treatment sessions are usually required.

• **Figure 13.** Telangiectasias in the chin area treated with Milesman Blauman®. Results after three sessions.

Diode laser treatment 545 nm:
COAGULATION EFFECT

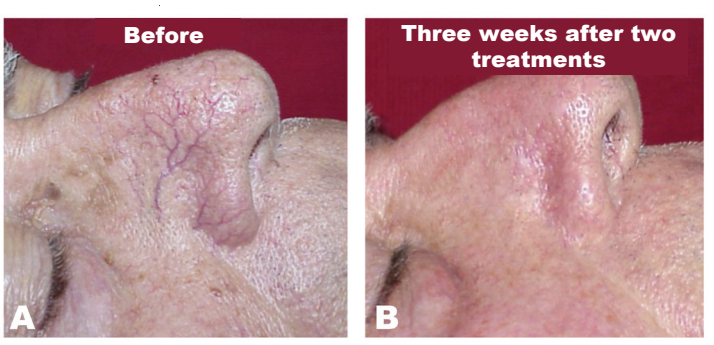

1 W, 0.5 mm beam diameter, 50 ms pulses, 100 ms pause, two treatments one month apart, performed without anesthesia.
A) Before treatment, obvious dilated telangiectases in thick skin.
B) Skin without residual lesions and disappearance of superficial unaesthetic varicose veins.

• **Figure 14.** Telangiectasias in nasal area treated with Milesman Blauman®.

TREATMENT OF VASCULAR LESIONS

Strawberry hemangiomas, venous lakes, and small vascular malformations can be treated with coagulation, as well as ruby spots, facial telangiectasias, and other vascular lesions. Figures 12-14 show cases of telangiectasias successfully removed with Milesman Blauman®.

The applied dosimetry was: Power =1W, Spot diameter: 0.5mm, Pulse Length=40ms, Delay=100ms. Two sessions were performed without anesthesia. Image A shows abundant small capillaries in the skin of the nose, prior to treatment with Milesman Blauman®. Image B, immediately after treatment without anesthesia, shows lesion of the first cutaneous layers with formation of bullae and signs of microhemorrhages. C) Three weeks after treatment the skin shows recovery with no residual lesions. Telangiectasias have been eliminated. Numbers 1 and 2, in the photograph on the right, show that the lesions caused by the laser treatment, seemingly significant, heal without scarring. It should be noted that this type of lesion responds well to coagulation treatment, particularly in thick skin, and equires very few sessions.

CUTTING EFFECTS

Figure 15 shows the sequence for the excision of a medium-sized sebaceous cyst on a patient's back which is causing concern for the patient who would like to have it removed. A) Marking to define the edges of the lesion and local anesthesia with Mepivacaine 2% with epinephrine.

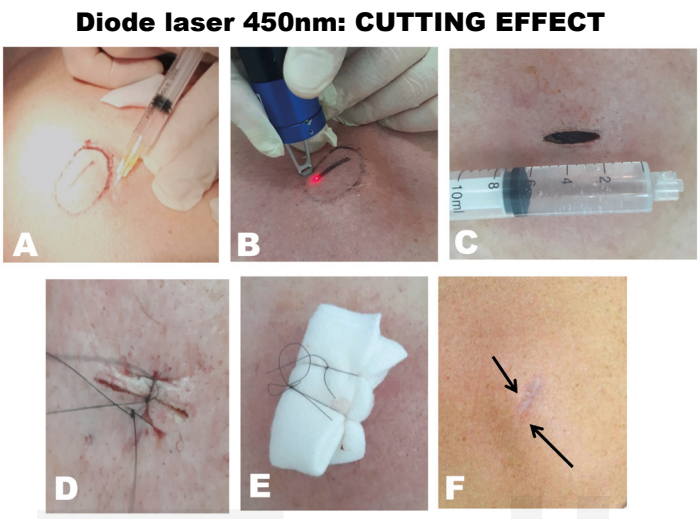

• **Figure 15.** Excision of a sebaceous cyst with Milesman Blauman®.

B) Skin marked with permanent black marker pen ink that acts as a barrier concentrating the laser energy, which cuts the skin with the 450nm beam, programmed for emission at 10 W, 40 ms pulse duration and 7.1 pulse frequency. Irradiation was quasi-continuous to maintain the thermal effect and to effectively cut the epidermis. Once through the epidermis there is no need to use the artificial pigment because the hemoglobin absorbs the blue beam well and allows the incision to be deepened without bleeding, until the cyst is located and separated for extraction. B and C) Show the cutting maneuver and the size of the incision to remove the lesion. D and E) Show the suture and protective bandage in place. F) Results 3 months after excision (black arrows). Healing occurred without complications and the patient reported good satisfaction with the result.

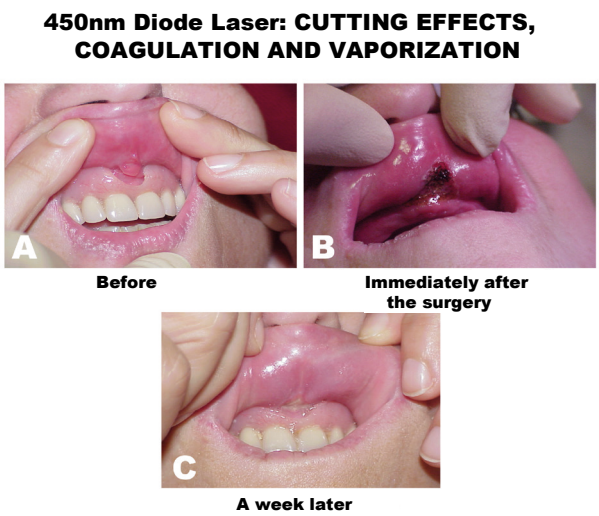

• **Figure 16.** Removal of the anomalous frenum in the mucosa of the upper lip, performed with Milesman Blauman®.

In Figure 16, we proceed to remove the frenum in the upper lip, which causes speech problems. B) Under local anesthesia and with laser programming at 10 W, 40 ms pulses and 100 ms pause, using the handpiece slightly defocused, tissue can be cut without bleeding. Vaporization and coagulation complement the cutting. Vaporization prevents bleeding. Thermal accumulation makes the three effects of the laser possible. Simply defocusing the laser impact point allows effective action due to the hemoglobin chromophore.
B) The appearance immediately after the surgery was completed. C) The appearance after one week. Oral mucosal lesions usually recover quickly, in part due to the abundant secretion of ptyalin.

DISCUSSION

The successful use of laser in medicine is due to its selective action which preserves as much as possible the integrity and/or viability of surrounding tissues, damage to which negatively effects scar repair. Precise laser interventions are based on the principle of selective photothermolysis which relies on these two key factors: 1. The absorption selectivity of the laser energy, which depends on the wavelength of the laser and, 2.

The composition of the target that should have a chromophore that at least preferentially absorbs the energy carried by the laser beam operating in a certain band of the light spectrum.

When skin defects are removed for cosmetic reasons, the first step is always to make an accurate diagnosis of the lesion to be treated; the second step is to adapt the laser protocol to the characteristics and chromophore arrangement of each lesion; and the third step is always to insist on the importance of topical maintenance treatments, more or less necessary or prolonged depending on the case, together with the use of sun photoprotectors. Also bearing in mind that, especially in aesthetic treatments, it is important to try to avoid complications such as hyperpigmentation, dyschromia, burns or scars.

As in other interventions, the addition of an exogenous chromophore can provide great advantages in the results (9,10). Under these conditions the energy fluence gradient in the underlying skin layers is drastically reduced (9-13), as the black ink acts as an interfering chromophore that absorbs and stops the laser pulses. Vaporization turns tissue into smoke and prevents coagulation of deeper layers of skin. In practice, the smoke created by vaporization can be observed.

The observation of smoke when the laser is irradiated on the lesion marked with black ink is an unequivocal demonstration of a clinically successful thermal effect. The vaporization effect with Milesman Blauman® using an optical barrier has been captured by real-time video-filming (14). Vaporization is very useful for removing various pigmented lesions and for facial rejuvenation. This, together with the demonstrated affinity of the 450nm laser for the chromophores hemoglobin and melanin, makes the Milesman Blauman® characteristics ideal for treatments on multiple vascular and pigmented lesions, as seen in the images illustrating this study. Ink marking is not recommended for these cases because the target chromophores are hemoglobin and melanin, respectively.

The histological and clinical results are consistent with the advantages that theoretically correspond to the 450nm laser in terms of its high selectivity for hemoglobin and melanin, according to previous comparative studies with different types of lasers (1-6,15,16). Details of these complex studies are not relevant here (16), but it is important to analyze what the advantages of Milesman Blauman® may be compared to other lasers available for the same uses.

Although the effectiveness of laser treatment depends on the absorption of its photons, thermal propagation is somewhat unavoidable because it is directly related to the time of action of the energy on the target. If a laser is used whose wavelength does not correspond to the chromophore of the target, the incident photons acting on the same spot produce destructive actions due to a thermal effect that is not selective, because the target lacks the absorbing chromophore. Essentially, we can adapt the time of the shot, the pause between pulses and the repetition, for example, to use the most appropriate parameters in skin lesions that require vaporization. On the other hand, we can use the coagulation effect if the incident energy density, even for the same laser, manages to progressively increase the heat deposit that changes the structure of the protein composition, causing coagulation.

To contain the laser energy, we can use a color barrier that serves as an absorbing chromophore, preferably capturing the light and, by absorption, limiting the depth of effect and thereby eliminating part of the epidermis. When using the laser to cut, the skin can be painted externally to protect the surface of the skin from thermal propagation. Once the skin has been cut in quasi-continuous by the high frequency of repetition of the pulses and intense absorption of the laser energy, the artificial pigment barrier is unnecessary because hemoglobin is also a chromophore with good absorption for 450nm. Small vessels will be coagulated which allows for further intervention in a bloodless field while penetrating the tissue.

In order to combine cutting, coagulation and vaporization, the laser must be programmed at high power in short, highly repetitive pulses, with programmed pauses between pulse trains if necessary to give the tissue a chance to cool down. This avoids thermal overload which diminshes the thermal effect where it is needed most, potentially causing complications in the healing process.

It is important to note that it is not a question of comparing the effectiveness of the 450nm diode laser, whose chromophores are mainly melanin and hemoglobin, to the cutting action, vaporization and coagulation of the CO_2 or Er: YAG laser, whose chromophore is water, and which are therefore much more effective for these actions. However, Milesman Blauman® effects are useful for employing fundamental thermal effects of the laser when a laser system whose chromophore is water is not available.

Regarding the optical barrier, in the case of a superficial pigmented lesion a non-permanent marker should be used, whereas in the case of pigmented lesions (whose color suggests a deep location of the pigment), the smaller molecules of permanent ink penetrate more deeply into the skin and allow a more intense marking of the target area. According to the verifications carried out, non-permanent ink molecules penetrate less into the skin and are useful for treating very superficial pigmented lesions, while permanent ink can "mark" deeper lesions.

The degree of hydration, homogeneity, specific variability of the tissue is very important during irradiation, to achieve any of the three effects, so if using a laser emission that does not correspond to the chromophore of the sample, the laser parameters must be adapted in terms of irradiance (the diameter of impact of the laser beam on the tissue), the frequency of the pulses (i.e. their time of action), and the pause time between them. Emission in the blue spectrum is normally subject to scattering characterized by an apparent "leakage" of energy due to the various components of the target tissue. Hence, in the case of the 450nm diode laser, tissues containing melanin and blood have high attenuation coefficients of the energy that is scattered to adjacent tissues. Therefore, the targeting must be carefully determined beforehand to achieve better and more precise effects.

CONCLUSIONS

This text presents the results of a preliminary investigation of this device, without any medical verifications. Initially, this equipment was only indicated in the treatment of acne, based on a trial methodology that was difficult to reproduce. We did not observe sufficiently effective results when trying to replicate it (17). The first verifications, presented here, indicate good and promising results, and justify continuing evaluation of the potential advantages of Milesman Blauman® for use in the treatment of benign skin lesions and in dermocosmetics. Thanks to innovative technology, the device is small, practical, safe, easy to transport and versatile with a variety of indications. Scientific support and observations from animals research and patient treatments demonstrate that Milesman Blauman® could rank high among the many lasers available for the treatment of various skin lesions. These initial observations indicate the need for clinical trials to confirm these results, to establish practice guidelines, and to better assess the potential advantages that Milesman Blauman® could have over other devices.

REFERENCES

1. Reichelt J, Winter J, Meister J, Frentzen M, Kraus D. *A novel blue light laser system for surgical applications in dentistry: evaluation of specific laser-tissue interactions in monolayer cultures.* Clin Oral Investig. 2017 May;21(4):985-994. doi: 10.1007/s00784-016-1864-6. Epub 2016 Jun 1. PMID: 27251194.

2. Braun A, Kettner M, Berthold M, Wenzler JS, Heymann PGB, Frankenberger R. *Efficiency of soft tissue incision with a novel 450nm semiconductor laser.* Lasers Med Sci. 2018 Jan;33(1):27-33. doi: 10.1007/s10103-017-2320-9. Epub 2017 Sep 9. PMID: 28889322.

3. Stein S, Kleye A, Schauseil M, Hellak A, Korbmacher-Steiner H, Braun A. *450nm diode laser-assisted debonding of self-ligating ceramic brackets. Biomed Tech (Berl).* 2017 Oct 26;62(5):513-520. doi: 10.1515/bmt-2016-0027. PMID: 28076292.

4. Palaia G, Impellizzeri A, Tenore G, Caporali F, Visca P, Del Vecchio A, Galluccio G, Polimeni A, Romeo U. *Ex vivo histological analysis of the thermal effects created by a 450nm diode laser in oral soft tissue biopsy.* Clin Oral Investig. 2020 Aug;24(8):2645-2652. doi: 10.1007/s00784-019-03123-4. Epub 2019 Nov 16. PMID: 31734792.

5. Saberi S, Rouzsaz M, Shafie F, Einizadeh S, Kharazifard MJ, Shahabi S. *The effect of laser-activated bleaching with 450nm and 915 nm diode lasers on enamel micro-hardness; an in vitro study.* Photodiagnosis Photodyn Ther. 2020 Sep;31:101952. doi: 10.1016/j.pdpdt.2020.101952. Epub 2020 Aug 18. PMID: 32818641.

6. Wenzler JS, Falk W, Frankenberger R, Braun A. *Impact of Adjunctive Laser Irradiation on the Bacterial Load of Dental Root Canals: A Randomized Controlled Clinical Trial. Antibiotics (Basel).* 2021 Dec 20;10(12):1557. doi: 10.3390/antibiotics10121557. PMID: 34943769; PMCID: PMC8698752.

7. UNE EN 60825-1 «Seguridad de los productos láser. *Parte 1: Clasificación del equipo, requisitos y guía de seguridad» 1996.* Modificada por: UNE EN 60825-1/Al 1: 1997 y con el complemento UNE EN 60825-1/A2: 2002.

8. Trelles MA. *Tratamiento del acné inflamatorio con láser de diodo de alta potencia (Milesman Blauman®): ensayo clínico e histológico.* Estudio editado y publicado en la web de milesman.com con link: https://www.milesman.com/wp-content/uploads/2023/02/Estudio_Cli%CC%81nico_sobre_Tratamiento_del_acne%CC%81_inflamatorio_con_la%CC%81ser_azul_milesman_blauman.pdf

9. Trelles MA, Verkruysse W, Sánchez J, Vélez M, Trelles K. *Improving the results of facial dermal lesions elimination by laser.* J Clin Laser Med Surg 1994;12:27-29.

10. Trelles MA, Almudever P, Alcolea JM, Cortijo J, Serrano G, Expósito I, Royo J, Leclère FM. *Cuttlefish Ink Melanin Encapsulated in Nanolipid Bubbles and Applied Through a Micro-Needling Procedure Easily Stains White Hair Facilitating Photoepilation.* J Drugs Dermatol 2016;15:615-25.

11. Van Gemert MJ, Welch AJ, Amin AP. *Is there an optimal laser treatment for port wine stains?* Lasers Surg Med 1986;6(1):76-83.

12. Trelles M, Allones I, Vélez M, Mordon S. *Nd: YAG laser combined with IPL treatment improves clinical results in non-ablative photorejuvenation.* J Cosmet Laser Ther 2004;6:69-78.

13. Trelles MA, Verkruysse W, Pickering JW, Sánchez J, Sala P. *A simple method to avoid depressed scarring in laser treatment of elevated lesions.* Plast Reconstr Surg. 1993 Jan;91(1):197.

14. Trelles MA. *Video-filmación a tiempo real de una vaporización superficial efectuada con Milesman Blauman tras marcaje de la lesión con tinta negra.* Instituto Médico Vilafortuny. Dubai. UAE.

15. Trelles MA, Vélez M, Rigau J. *Interacción de la luz con los tejidos. En: Cisneros JL, Camacho FM, Trelles MA. Láser en Dermatología y Dermocosmética.* Ed. Aula Médica, Segunda Edición, 2008.

16. Bashkatov AN, Genina EA, Tuchin VV. *Optical properties of skin, subcutaneous and muscle tissues;* a review Journal of Innovative Optical Health Sciences 2011 04:01, 9-38.

17. Torregrosa JL, Rodríguez S, Amarelo J, Segura L. *Clinical evaluation of the safety and efficacy of the Milesman 450nm blue laser on acne inflammatory lesions.* ClinicalTrials.gov. Code: NCT046982239.

The author declares that the costs of all tests carried out have been covered by the manufacturer of the equipment and that the results shown are those that were obtained from the investigations carried out.